

# Retinal Nerve Fiber Layer Thickness in Dominant Optic Atrophy

## Measurements by Optical Coherence Tomography and Correlation with Age

Piero Barboni, MD,<sup>1,2</sup> Giacomo Savini, MD,<sup>3</sup> Vincenzo Parisi, MD,<sup>3</sup> Michele Carbonelli, MD,<sup>1</sup> Chiara La Morgia, MD,<sup>2</sup> Alessandra Maresca, PhD,<sup>2</sup> Federico Sadun, MD,<sup>4</sup> Anna Maria De Negri, MD,<sup>5</sup> Arturo Carta, MD,<sup>6</sup> Alfredo A. Sadun, MD, PhD,<sup>7</sup> Valerio Carelli, MD, PhD<sup>2</sup>

**Purpose:** To measure the retinal nerve fiber layer (RNFL) thickness by means of optical coherence tomography (OCT) in patients with dominant optic atrophy (DOA).

**Design:** Cross-sectional study.

**Participants:** Thirty-three patients from 15 pedigrees with DOA harboring heterozygous mutations in the *OPA1* gene and 43 healthy subjects were enrolled.

**Methods:** The RNFLs of DOA patients were studied by OCT and compared with those of 43 healthy subjects matched for age and optic nerve head (ONH) size.

**Main Outcome Measures:** Retinal nerve fiber layer thickness.

**Results:** Dominant optic atrophy patients revealed a significant RNFL thickness reduction in all quadrants, with a preferential involvement of the temporal and inferior sectors. The progressive decline of RNFL thickness with age was similar to that observed in healthy subjects and was more evident in the 2 quadrants with higher residual amounts of fibers, that is, the superior and the inferior. The temporal quadrant was profoundly depleted of fiber so that the further rate of loss of microns per year is close to zero, whereas the nasal quadrant was spared the most by neurodegeneration.

**Conclusions:** The present findings, taken in conjunction with the authors' previous description of small ONH size in DOA, strongly suggest that patients with this disease are born with fewer optic nerve axons and support the hypothesis that subsequent visual loss depends on further age-related loss of fibers, which also occurs in controls.

**Financial Disclosure(s):** The author(s) have no proprietary or commercial interest in any materials discussed in this article. *Ophthalmology* 2011;118:2076–2080 © 2011 by the American Academy of Ophthalmology.



Dominant optic atrophy (DOA), initially described by Kjer,<sup>1</sup> is a genetic neurodegenerative disorder affecting the retinal ganglion cells and characterized by a slowly progressive bilateral visual loss starting in childhood, ultimately leading to severe optic atrophy.<sup>2</sup> Approximately 60% of DOA cases harbor a heterozygous mutation in the *OPA1* gene (3q28–q29, Online Mendelian Inheritance in Man 165500),<sup>3</sup> a dynamin-related guanosine triphosphate (GTPase) targeted to mitochondria involved in multiple functions, including mitochondrial fusion, cristae morphologic features, oxidative phosphorylation (OXPHOS) and membrane potential maintenance, and control of apoptosis.<sup>4</sup> Over 200 *OPA1* mutations have been reported (<http://lbbma.univ-angers.fr/eOPA1/>, accessed January 11, 2011), and most are predicted to induce haploinsufficiency, but missense mutations also are found commonly, and a subset of these, remarkably affecting the GTPase domain, are associated with a complicated form of syndromic DOA (DOA plus) character-

ized by the accumulation of mitochondrial DNA multiple deletions.<sup>5–7</sup>

Clinical examination demonstrates loss of vision, impairments of color vision, cecocentral scotomas, and temporal or diffuse pallor of the optic disc, which often leads to optic disc excavation. Disease progression may be quite variable within the same family, ranging from mild cases with minimal losses of visual acuity that stabilizes in adolescence, to slowly but relentlessly progressing cases, to cases with subacute severe decreases of visual acuity. This variability of clinical expression may be reflected by the different extent of optic atrophy in different patients. Dominant optic atrophy, similarly to Leber's hereditary optic neuropathy (LHON), is characterized by the early and preferential involvement of the small fibers in the papillomacular bundle, a hallmark of mitochondrial optic neuropathies.<sup>8</sup>

Optical coherence tomography (OCT) has been used successfully by the authors' group to redefine by objective anatomic measures the features of optic neuropathy in

Table 2. Mean ( $\pm$ Standard Deviation) Values of Optic Nerve Head Area and Retinal Nerve Fiber Layer Thickness for Patients with Dominant Optic Atrophy and Controls

	Dominant Optic Atrophy Group 1 (Higher Visual Acuity)	Dominant Optic Atrophy Group 2 (Lower Visual Acuity)	Controls	P Value
Optic nerve head area (mm <sup>2</sup> )	1.84 $\pm$ 0.34	1.79 $\pm$ 0.32	1.77 $\pm$ 0.17	NS*
Average thickness ( $\mu$ m)	62.20 $\pm$ 10.66	60.10 $\pm$ 11.90	96.30 $\pm$ 8.2	<0.0001*
Temporal thickness ( $\mu$ m)	34.33 $\pm$ 6.27	32.50 $\pm$ 5.40	68.23 $\pm$ 13.88	<0.0001
Superior thickness ( $\mu$ m)	86.30 $\pm$ 18.24	82.66 $\pm$ 21.05	120.47 $\pm$ 14.03	<0.0001
Nasal thickness ( $\mu$ m)	55.49 $\pm$ 11.29	53.97 $\pm$ 15.91	75.32 $\pm$ 13.41	<0.0001
Inferior thickness ( $\mu$ m)	72.12 $\pm$ 18.41	70.16 $\pm$ 19.97	120.30 $\pm$ 16.20	<0.0001

NS = not significant.  
\*Kruskal-Wallis test.

LHON,<sup>9,10</sup> including the tempo of the axonal loss resulting from the progression of neurodegeneration.<sup>11,12</sup> Optical coherence tomography also was used to study the optic nerve head (ONH) conformation and size in LHON,<sup>13</sup> and more recently in DOA patients with *OPA1* mutations, showing that they present a smaller ONH compared with controls.<sup>14</sup> Only a few studies investigated the peripapillary retinal nerve fiber layer (RNFL) thickness in small series of DOA patients, showing the thinning of the RNFL.<sup>15–17</sup> Although these findings are interesting, one study was flawed by the lack of a control group,<sup>15</sup> and the others were limited by small sample sizes.<sup>16,17</sup>

Herein the results are presented of an investigation by OCT of the RNFL in a large series of Italian DOA patients carrying a pathogenic heterozygous mutation in the *OPA1* gene, compared with a control group of healthy subjects matched for age and ONH size.

## Patients and Methods

All DOA patients included in the present study had a molecularly confirmed diagnosis of a *OPA1* mutation (Table 1, available at <http://aaojournal.org>) and were evaluated prospectively at the Department of Neurological Sciences, University of Bologna, between 2002 and 2009. Thirty-three patients (mean age, 35.4 $\pm$ 21.8 years; range, 7–78 years) from 15 unrelated pedigrees were recruited. All subjects had an extensive ophthalmologic examination, including best-corrected visual acuity measurement (reported as the logarithm of the minimum angle of resolution), slit-lamp biomicroscopy, intraocular pressure measurement, indirect ophthalmoscopy, and optic nerve head photography. Exclusion criteria were the presence of any retinal pathologic features, optic nerve disease other than DOA, or both and spherical or cylindrical refractive errors, or both, higher than 3 and 2 diopters (D), respectively. All participants gave their informed consent according to the Declaration of Helsinki, and the study was approved by the internal review board of the Department of Neurological Sciences, University of Bologna.

Patients were compared with a control group consisting of 43 eyes from 43 healthy subjects (mean age, 37.5 $\pm$ 14.0 years; range, 10–79 years) selected from a larger database of healthy subjects prospectively enrolled in previous investigations.<sup>9,18,19</sup> Because both age and disc area have been shown to influence RNFL thickness as measured by OCT,<sup>18–22</sup> these cases were matched for optic disc area as well as age (see Table 2) and were from volunteers and patients with no pathologic features other than minor refractive disorders.

## Instrumentation and Procedures

All subjects underwent RNFL thickness measurement and ONH analysis by OCT (StratusOCT, software version 4.0.1; Carl Zeiss Meditec, Inc., Dublin, CA). The respective acquisition protocols adopted were RNFL Thickness 3.4 and Fast Optic Disc, as previously reported.<sup>18</sup> For each eye, the mean RNFL thickness (360° measure), temporal quadrant thickness (316°–45° unit circle), superior quadrant thickness (46°–135°), nasal quadrant thickness (136°–225°), and inferior quadrant thickness (226°–315°) were studied, all automatically calculated by OCT using the existing software.

The examination was performed under mydriasis by an experienced operator (MC). At the beginning of the examination, the OCT lenses were adjusted for the patient's refractive error, which was within  $\pm$ 3 D of emmetropia in all subjects. Polarization was optimized to maximize the reflective signal, and the best centration of the scan with respect to the optic disc was always selected. Internal fixation was used whenever possible; patients with low central vision were asked to look laterally during the scan acquisition until the image of the optic disc appeared on the screen of the operator. When the fellow eye allowed it, external fixation was adopted.

## Statistical Analysis

The 2 eyes of each patient were analyzed separately, such that statistical analysis was carried out on group 1, including the eye with the highest visual acuity, and group 2, the eye with the lowest visual acuity. After the Gaussian distribution was assessed by the

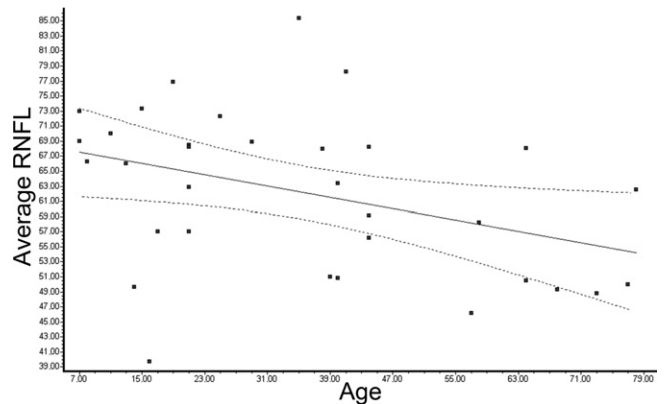


Figure 1. Graph showing that in group 1, linear regression disclosed a statistically significant reduction of 360° average retinal nerve fiber layer (RNFL) thickness as age increased ( $P = 0.027$ ;  $r = -0.382$ ;  $r^2 = 0.146$ ). — Linear regression; - - - 95% confidence interval.

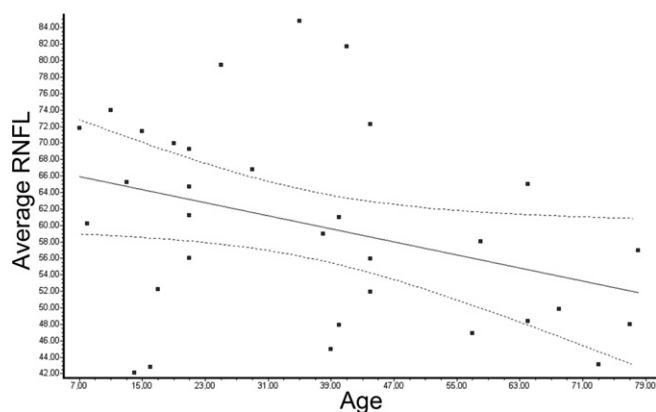


Figure 2. Graph showing that in group 2, linear regression disclosed a statistically significant reduction of 360° average retinal nerve fiber layer (RNFL) thickness as age increased ( $P = 0.043$ ;  $r = -0.358$ ;  $r^2 = 0.128$ ). —Linear regression; - - - 95% confidence interval.

method of Kolmogorov and Smirnov, the mean values of controls and patients were compared by ordinary analysis of variance with the Dunn test for parametric data and the Kruskal-Wallis test with Dunn posttest for nonparametric data. The relationship between the RNFL thickness and age was assessed by linear regression. A  $P < 0.05$  was accepted as statistically significant. All statistical analyses were performed using GraphPad InStat software version 3a for Macintosh (GraphPad Software, San Diego, CA; [www.graphpad.com](http://www.graphpad.com), accessed February 15, 2011).

## Results

Data from OCT analysis were available for all 33 eyes of group 1 (higher visual acuity) and for 32 eyes of group 2 (lower visual acuity). Mean visual acuity was  $0.81 \pm 0.44$  logarithm of the minimum angle of resolution units for group 1 eyes and  $0.92 \pm 0.44$  logarithm of the minimum angle of resolution units for group 2 eyes ( $P > 0.05$ ). Compared with controls, both group 1 and 2 showed reduced RNFL thickness in all 4 quadrants and in the 360° average measurement (Table 2). No statistically significant differences were detected between eyes of groups 1 and 2, although the values of group 1 were higher than those of group 2 in all quadrants and in the 360° average measurement.

In comparison with the control group, the reduction of the RNFL thickness was more evident in the temporal quadrant, where it was decreased by 49.7% (group 1) and 52.4% (group 2), and in

the inferior quadrant, where it was decreased by 40.0% (group 1) and 41.7% (group 2). Retinal nerve fiber layer thinning was less consistent in the superior quadrant (group 1, 28.4%; group 2, 31.4%) and the nasal quadrant (group 1, 26.3%; group 2, 28.3%).

In eyes of group 1, linear regression disclosed a statistically significant relationship between age and 360° average RNFL thickness ( $P = 0.027$ ;  $r = -0.382$ ;  $r^2 = 0.146$ ; Fig 1), with the latter decreasing  $0.19 \mu\text{m}/\text{year}$  (95% confidence interval,  $-0.35$  to  $-0.02$ ). The linear regression was statistically significant in the superior ( $P = 0.013$ ;  $r = -0.427$ ;  $r^2 = 0.182$ ) and inferior ( $P = 0.027$ ;  $r = -0.383$ ;  $r^2 = 0.147$ ) quadrants, whereas no relationship between age and RNFL thickness was detected for the temporal and nasal quadrants. The superior and inferior quadrants contributed mostly to the age-related decrease of RNFL thickness, because their slopes were, respectively,  $-0.36 \mu\text{m}/\text{year}$  and  $-0.32 \mu\text{m}/\text{year}$ . The rate of RNFL thickness decrease per year was low in the nasal quadrant ( $-0.13 \mu\text{m}/\text{year}$ ) and close to 0 in the temporal quadrant ( $0.05 \mu\text{m}/\text{year}$ ). No relationship was detected between 360° average RNFL thickness and optic nerve head area.

In eyes of group 2, linear regression disclosed a statistically significant relationship between age and 360° average RNFL thickness ( $P = 0.043$ ;  $r = -0.358$ ;  $r^2 = 0.128$ ; Fig 2), with the latter decreasing  $0.20 \mu\text{m}/\text{year}$  (95% confidence interval,  $-0.39$  to  $-0.01$ ). The linear regression was statistically significant in the superior quadrant ( $P = 0.013$ ;  $r = -0.432$ ;  $r^2 = 0.186$ ) and close to statistical significance in the inferior quadrant ( $P = 0.068$ ;  $r = -0.326$ ;  $r^2 = 0.106$ ). No relationship between age and RNFL thickness was detected for the temporal and nasal quadrants. The superior and inferior quadrants contributed mostly to the age-related decrease of RNFL thickness, because their slopes were, respectively,  $-0.42 \mu\text{m}/\text{year}$  and  $-0.30 \mu\text{m}/\text{year}$ . The rate of RNFL thickness decrease per year was close to 0 in the nasal ( $-0.02 \mu\text{m}/\text{year}$ ) and temporal ( $-0.04 \mu\text{m}/\text{year}$ ) quadrants. No relationship was detected between 360° average RNFL thickness and optic nerve head area.

The relationship between RNFL thickness and age was statistically significant also in the control group, where the regression line for the 360° average measurement ( $P = 0.0004$ ;  $r = -0.517$ ;  $r^2 = 0.268$ ) produced a slope of  $0.30 \mu\text{m}/\text{year}$ . The linear regression was statistically significant in the inferior ( $P = 0.022$ ;  $r = -0.347$ ;  $r^2 = 0.120$ ) and nasal ( $P = 0.012$ ;  $r = -0.376$ ;  $r^2 = 0.141$ ) quadrants and close to statistical significance in the superior quadrant ( $P = 0.088$ ;  $r = -0.263$ ;  $r^2 = 0.069$ ). No relationship between age and RNFL thickness was detected for the temporal quadrant. The inferior and nasal quadrants showed a maximum tendency to decline with age, because their slopes were, respectively,  $-0.40 \mu\text{m}/\text{year}$  and  $-0.36 \mu\text{m}/\text{year}$ . The rate of RNFL thickness decrease per year was lower in the superior quadrant ( $-0.26 \mu\text{m}/\text{year}$ ) and temporal quadrant ( $-0.16 \mu\text{m}/\text{year}$ ).

Table 3. Age-Related Retinal Nerve Fiber Layer Thickness Decrease in Previous Studies Compared with the Present Investigation

	Present Study: controls (n = 43)	Sung et al <sup>21</sup> (n = 226)	Parikh et al <sup>20</sup> (n = 187)	Budenz et al <sup>22</sup> (n = 328)	Present Study: Dominant Optic Atrophy Group 1 (n = 33)	Present Study: Dominant Optic Atrophy Group 2 (n = 32)
Average	-0.30*	-0.25*	-0.16*	-0.20*	-0.20*	-0.19*
Temporal quadrant	-0.16	-0.06	-0.20*	NA	-0.02	0.05
Superior quadrant	-0.26	-0.34*	-0.23*	NA	-0.42*	-0.36*
Nasal quadrant	-0.36*	-0.24*	-0.12	NA	-0.04	-0.13
Inferior quadrant	-0.40*	-0.36*	-0.08	NA	-0.30*	-0.32*

NA = not available.

Values are expressed as micrometers/year.

\* $P < 0.05$ .

## Discussion

This study, the largest to date investigating DOA patients by OCT, showed that in these eyes, the RNFL thickness is reduced in all quadrants compared with healthy subjects. The loss of axons follows a gradient, with the temporal and inferior quadrants being earlier and more consistently affected. This pattern remarkably matches that observed in LHON, confirming the vulnerability of the small fibers of the papillomacular bundle in mitochondrial optic neuropathies. Remarkably, the thinning of the RNFL progresses with age. This is particularly obvious in the superior and inferior quadrants. The temporal quadrant likely already has undergone a marked thinning at early age or congenitally, and hence further losses are less evident. However, the nasal quadrant is the least involved in DOA, as in other mitochondrial optic neuropathies.

Other authors have reported similar results. Kim and Hwang<sup>15</sup> compared the RNFL thickness measurements of DOA patients with those in the normative database provided by StratusOCT and found that thinning was more evident in the temporal quadrant. Involvement of the other quadrants in their study seemed less important, but they did not use their own control group, possibly weakening their findings.<sup>15</sup> Ito et al<sup>17</sup> and, more recently, Milea et al,<sup>16</sup> compared, respectively, 8 and 10 DOA patients with controls and disclosed a significant thinning of the RNFL thickness in all quadrants. These 3 studies reported a preferential and more consistent involvement of the temporal quadrant, and this is corroborated by the present findings. Only the study by Milea et al<sup>16</sup> showed that the inferior quadrant was the second most affected, a finding that is now established by the current results. We previously showed that the inferior is the second most affected quadrant (after the temporal) also in LHON.<sup>12</sup> It is not surprising that both in DOA and LHON the degenerative process first involves the most vulnerable, small axons of the papillomacular bundle and progresses contiguously to the larger, adjacent axons.

This study also demonstrated an association between progressive RNFL thinning and age, which in DOA was statistically significant for 2 of the 4 quadrants and the overall average. Interestingly, RNFL thinning was noted in controls as a function of age as well. Attrition of axons with age has been demonstrated by histopathologic analysis.<sup>23</sup> Indeed, Kim et al<sup>24</sup> attributed delayed visual decline in patients with stable optic neuropathy to this superimposed dynamic. Milea et al<sup>16</sup> argued that in DOA, there is also a superimposed loss of axons associated with increasing age. However, they did not directly demonstrate this as statistically significant because of the small sample size. In fact, they showed comparable rates of thinning in both DOA and control subjects. This result led the authors to postulate that in DOA, “the gradual reduction in best corrected visual acuity with age may be a consequence of a relative deficit in RNFL thickness that is established before the second decade of life.” The current data confirm this hypothesis, as a statistically significant decrease in the 360° average RNFL thickness in group 1 (0.19  $\mu\text{m}/\text{year}$ ) and group 2 (0.20  $\mu\text{m}/\text{year}$ ) was detected. The decrease in the 360° average RNFL thickness in both DOA groups in the current study lies between those reported for healthy subjects by Parikh et al<sup>20</sup>

(0.16  $\mu\text{m}/\text{year}$ ), Sung et al<sup>21</sup> (0.25  $\mu\text{m}/\text{year}$ ), and Budenz et al<sup>22</sup> (0.20  $\mu\text{m}/\text{year}$ ), using the same technology (Table 3). However, the current data for the control group showed a steeper slope (0.30  $\mu\text{m}/\text{year}$ ), possibly because of the smaller sample size. Additionally, the control group was matched to DOA patients for ONH size, and this also may have influenced the results, because the mean optic disc area in this study is smaller than that of the above-mentioned studies.

Optic nerve head size may be very relevant. It was demonstrated previously that in DOA patients, the ONH size was significantly smaller than in age-matched controls.<sup>14</sup> This is further evidence that DOA patients have a smaller population of axons at birth and the subsequent age-related loss impacts on the natural progression of the optic neuropathy in DOA. In the present study, DOA patients were not evaluated longitudinally, and future longitudinal studies are warranted to confirm the current results as well as to investigate the relationship between visual acuity decline and RNFL thickness.

A study of the developing retina from mouse embryos showed that *OPAI* expression appeared as early as embryos day 15 (E15) in the prospective ganglion cell layer, becoming very strong just before birth at E17 only in the ganglion cell layer of the retina.<sup>25</sup> Another study of early murine postnatal retina showed the most intense *OPAI* expression confined to the ganglion cell layer and the adjacent inner plexiform layer from postnatal day 3 (P3) through P5, extending to the inner row of the inner nuclear layer by P10.<sup>26</sup> These studies point to a relevant role of *OPAI* in the retinal ganglion cell system of the developing retina, strongly suggesting that mutant *OPAI* may translate in a developmental defect affecting number of retinal ganglion cells and ONH anatomic characteristics. It would be of great interest to investigate this issue in the developing retina of embryos and in the early postnatal stages of the recently established mouse models of DOA.<sup>27,28</sup>

In conclusion, these results show that DOA patients reveal a RNFL thickness reduction in all quadrants, with a preferential involvement of the temporal and inferior sectors. The decline of RNFL thickness with age is similar to that observed in healthy subjects and is more evident in 2 quadrants with higher residual amounts of fibers, that is, the superior quadrant, followed by the inferior quadrant. The temporal fibers already are so depleted that the further rate of loss of microns per year is close to 0. The present findings, taken in conjunction with the previous description of small ONH size in DOA, strongly suggest that patients with this disease are born with fewer optic nerve axons.

## References

1. Kjer P. Infantile optic atrophy with dominant mode of inheritance: a clinical and genetic study of 19 Danish families. *Acta Ophthalmol Suppl* 1959;164(suppl):1–147.
2. Newman NJ. Hereditary optic neuropathies. In: Miller NR, Newman NJ, eds.; Biousse V, Kerrison JB, assoc. eds. Walsh and Hoyt's Clinical Neuro-Ophthalmology. 6th ed. vol 1. Philadelphia: Lippincott Williams & Wilkins; 2005:465–501.



3. Yu-Wai-Man P, Griffiths PG, Burke A, et al. The prevalence and natural history of dominant optic atrophy due to *OPA1* mutations. *Ophthalmology* 2010;117:1538–46.
4. Liesa M, Palacín M, Zorzano A. Mitochondrial dynamics in mammalian health and disease. *Physiol Rev* 2009;89:799–845.
5. Amati-Bonneau P, Valentino ML, Reynier P, et al. *OPA1* mutations induce mitochondrial DNA instability and optic atrophy ‘plus’ phenotypes. *Brain* 2008;131:338–51.
6. Hudson G, Amati-Bonneau P, Blakely EL, et al. Mutation of *OPA1* causes dominant optic atrophy with external ophthalmoplegia, ataxia, deafness and multiple mitochondrial DNA deletions: a novel disorder of mtDNA maintenance. *Brain* 2008;131:329–37.
7. Yu-Wai-Man P, Griffiths PG, Gorman GS, et al. Multi-system neurological disease is common in patients with *OPA1* mutations. *Brain* 2010;133:771–86.
8. Carelli V, Ross-Cisneros FN, Sadun AA. Mitochondrial dysfunction as a cause of optic neuropathies. *Prog Retin Eye Res* 2004;23:53–89.
9. Barboni P, Savini G, Valentino ML, et al. Retinal nerve fiber layer evaluation by optical coherence tomography in Leber’s hereditary optic neuropathy. *Ophthalmology* 2005;112:120–6.
10. Savini G, Barboni P, Valentino ML, et al. Retinal nerve fiber layer evaluation by optical coherence tomography in unaffected carriers with Leber’s hereditary optic neuropathy mutations. *Ophthalmology* 2005;112:127–31.
11. Barboni P, Savini G, Valentino ML, et al. Leber’s hereditary optic neuropathy with childhood onset. *Invest Ophthalmol Vis Sci* 2006;47:5303–9.
12. Barboni P, Carbonelli M, Savini G, et al. Natural history of Leber’s hereditary optic neuropathy: longitudinal analysis of the retinal nerve fiber layer by optical coherence tomography. *Ophthalmology* 2010;117:623–7.
13. Ramos C do V, Bellusci C, Savini G, et al. Association of optic disc size with development and prognosis of Leber’s hereditary optic neuropathy. *Invest Ophthalmol Vis Sci* 2009;50:1666–74.
14. Barboni P, Carbonelli M, Savini G, et al. *OPA1* mutations associated with dominant optic atrophy influence optic nerve head size. *Ophthalmology* 2010;117:1547–53.
15. Kim TW, Hwang JM. Stratus OCT in dominant optic atrophy: features differentiating it from glaucoma. *J Glaucoma* 2007;16:655–8.
16. Milea D, Sander B, Wegener M, et al. Axonal loss occurs early in dominant optic atrophy. *Acta Ophthalmol* 2010;88:342–6.
17. Ito Y, Nakamura M, Yamakoshi T, et al. Reduction of inner retinal thickness in patients with autosomal dominant optic atrophy associated with *OPA1* mutations. *Invest Ophthalmol Vis Sci* 2007;48:4079–86.
18. Savini G, Zanini M, Carelli V, et al. Correlation between retinal nerve fibre layer thickness and optic nerve head size: an optical coherence tomography study. *Br J Ophthalmol* 2005;89:489–92.
19. Savini G, Barboni P, Carbonelli M, Zanini M. The effect of scan diameter on retinal nerve fiber layer thickness measurement using Stratus optic coherence tomography. *Arch Ophthalmol* 2007;125:901–5.
20. Parikh RS, Parikh SR, Sekhar GC, et al. Normal age-related decay of retinal nerve fiber layer thickness. *Ophthalmology* 2007;114:921–6.
21. Sung KR, Wollstein G, Bilonick RA, et al. Effects of age on optical coherence tomography measurements of healthy retinal nerve fiber layer, macula and optic nerve head. *Ophthalmology* 2009;116:1119–24.
22. Budenz DL, Anderson DR, Varma R, et al. Determinants of normal retinal nerve fiber layer thickness measured by Stratus OCT. *Ophthalmology* 2007;114:1046–52.
23. Johnson BM, Miao M, Sadun AA. Age-related decline of human optic nerve axon populations. *Age* 1987;10:5–9.
24. Kim JW, Rizzo JF, Lessell S. Delayed visual decline in patients with “stable” optic neuropathy. *Arch Ophthalmol* 2005;123:785–8.
25. Aijaz S, Erskine L, Jeffery G, et al. Developmental expression profile of the optic atrophy gene product: *OPA1* is not localized exclusively in the mammalian retinal ganglion cell layer. *Invest Ophthalmol Vis Sci* 2004;45:1667–73.
26. Pesch UE, Fries JE, Bette S, et al. *OPA1*, the disease gene for autosomal dominant optic atrophy, is specifically expressed in ganglion cells and intrinsic neurons of the retina. *Invest Ophthalmol Vis Sci* 2004;45:4217–25.
27. Alavi MV, Bette S, Schimpf S, et al. A splice site mutation in the murine *Opal* gene features pathology of autosomal dominant optic atrophy. *Brain* 2007;130:1029–42.
28. Davies VJ, Hollins AJ, Piechota MJ, et al. *Opal* deficiency in a mouse model of autosomal dominant optic atrophy impairs mitochondrial morphology, optic nerve structure and visual function. *Hum Mol Genet* 2007;16:1307–18.

## Footnotes and Financial Disclosures

Originally received: October 18, 2010.

Final revision: February 15, 2011.

Accepted: February 15, 2011.

Available online: May 31, 2011.

Manuscript no. 2010-1444.

<sup>1</sup> Studio Oculistico d’Azeglio, Bologna, Italy.

<sup>2</sup> Dipartimento di Scienze Neurologiche, Università di Bologna, Bologna, Italy.

<sup>3</sup> Fondazione G.B. Bietti-IRCCS, Roma, Italy.

<sup>4</sup> Ospedale San Giovanni, Tivoli, Italy.

<sup>5</sup> Azienda San Camillo-Forlanini, Rome, Italy.

<sup>6</sup> Sezione di Oftalmologia, Università di Parma, Parma, Italy.

<sup>7</sup> Doheny Eye Institute and Department of Ophthalmology, Keck School of Medicine of the University of the Southern California, Los Angeles, California.

Financial Disclosure(s):

The author(s) have no proprietary or commercial interest in any materials discussed in this article.

Supported in part by Telethon, Italy (grant no.: GGP06233 [VC]).

Correspondence:

Piero Barboni, MD, Studio Oculistico d’Azeglio, Via d’Azeglio 5, Bologna 40123, Italy. E-mail: [p.barboni@studiodazeglio.it](mailto:p.barboni@studiodazeglio.it).