



Surgery for Idiopathic Epimacular Membrane: Morpho-Functional Outcomes Based on the Preoperative Macular Integrity of the Photoreceptor Junction. A Prospective Pilot Study

Giulio Ruberto · Vincenzo Parisi · Giulio Vandelli · Alessandro Falcione ·

Federica Manzoni · Ivano Riva · Luciano Quaranta

Received: September 24, 2019
© Springer Healthcare Ltd., part of Springer Nature 2019

ABSTRACT

Introduction: This study aimed to evaluate whether the preoperative integrity of the inner segment (IS) and outer segment (OS) photoreceptor junction may influence the postoperative visual acuity, the macular morphology [assessed by spectral domain optical coherence tomography (SD-OCT)], and macular function (evaluated by multifocal electroretinogram, mfERG) in patients with idiopathic epimacular membrane (EMM) followed up for 6 months.

Methods: In this observational prospective study, 18 patients with EMM (mean age 72.5 ± 6.87 years) were enrolled. They were divided into two groups according to the preoperative integrity of the SD-OCT IS/OS

junction: the EMM-I group with an intact IS/OS junction (11 patients, mean age 72.75 ± 3.49 years, providing 11 eyes) and the EMM-D group with a disrupted IS/OS junction (7 patients, mean age 70.86 ± 10.79 years, providing 7 eyes). For each enrolled patient, visual acuity (VA), mfERG, and SD-OCT were assessed at baseline (preoperative) and after 1, 3, and 6 months of follow-up after surgical treatment for EMM (pars plana vitrectomy with EMM removal and internal limiting membrane peeling).

Results: During the whole follow-up, VA was significantly increased in EMM-I eyes and unmodified in EMM-D eyes. In both groups, mfERG responses were not significantly different and not related to VA differences. In EMM-I eyes a significant reduction of central retinal thickness (CRT) was observed; however, it was not correlated with VA changes. In EMM-D eyes CTR was not significantly reduced, whereas macular volume was significantly reduced. These changes were significantly related to the corresponding differences in VA.

Conclusions: Our results suggest that the preoperative evaluation of the integrity of the IS/OS junction is relevant for postoperative outcomes. The recovery in VA was higher in EMM-I eyes than in EMM-D eyes. Postoperative recovery was not associated with morphology of the outer retina (photoreceptor and outer nuclear layer) and the function of preganglionic elements.

Enhanced Digital Features To view enhanced digital features for this article go to <https://doi.org/10.6084/m9.figshare.10321052>.

G. Ruberto · G. Vandelli · A. Falcione · L. Quaranta
Department of Surgical & Clinical, Diagnostic and Pediatric Sciences, Section of Ophthalmology, University of Pavia, IRCCS Fondazione Policlinico San Matteo, Pavia, Italy

V. Parisi (✉) · I. Riva
IRCCS Fondazione Bietti, Rome, Italy
e-mail: vincenzo.parisi@fondazionebietti.com

F. Manzoni
Scientific Direction, Clinical Epidemiology and Biometry Unit, San Matteo Hospital Foundation, Pavia, Italy

Keywords: Epimacular membrane; Internal limiting membrane peeling; mfERG; OCT; Ophthalmology

Key Summary Points

Why carry out this study?

It was suggested that the preoperative integrity of the junction between the inner and the outer segments of photoreceptors (IS/OS junction) observed by spectral domain optical coherence tomography (SD-OCT) is a prognostic factor for visual function recovery after epimacular membrane (EMM) surgery.

Multifocal electroretinogram (mfERG) is an interesting tool for assessing the functional changes of the macular preganglionic elements before and after surgical removal of EMM.

This monocentric and prospective study was carried out to evaluate whether the presence of preoperative integrity of the IS/OS junction may influence the postoperative visual acuity, the macular morphology (assessed by SD-OCT), and macular function (evaluated by mfERG) in patients with EMM followed up for 6 months.

What was learned from the study?

During the whole follow-up, VA was significantly increased in eyes with IS/OS junction integrity (EMM-I eyes) and unmodified in those with disrupted IS/OS junction (EMM-D eyes). In both groups, mfERG responses were not significantly different and not related to VA differences. In EMM-I eyes a significant reduction of central retinal thickness (CRT) was observed; however, it was not correlated with VA changes. In EMM-D eyes CRT was not significantly reduced, whereas macular volume was significantly reduced. These changes were significantly related to the corresponding differences in VA.

The preoperative evaluation of the integrity of the IS/OS junction is relevant for postoperative outcomes. The recovery in VA was higher in EMM-I eyes than in EMM-D eyes.

Postoperative recovery was not associated with morphology of the outer retina (photoreceptor and outer nuclear layer) and the function of the preganglionic element.

INTRODUCTION

Idiopathic epimacular membrane (EMM) is a vitreomacular interface disorder significantly associated with aging and posterior vitreous detachment (PVD). Symptoms consist in visual impairment, blurred vision, and metamorphopsia. EMM is characterized by the development of a fibrocellular sheet-like structure on the inner surface of the retina. The major cellular components are the retinal glial cells while the extracellular matrix is represented by an irregular network of different types of collagen fibrils [1].

Surgical treatment for symptomatic EMM is pars plana vitrectomy with EMM removal. Internal limiting membrane (ILM) peeling is also performed to prevent its recurrence [2], since ILM acts as a scaffold for the EMM components [2, 3].

In relation to prognostic factors for visual function recovery after surgery, Falkner-Radler et al. [4] suggested that a subjective recovery of visual acuity (VA) may be reached when preoperative integrity of the junction between the inner (IS) and the outer segments (OS) of photoreceptors can be observed by using spectral domain optical coherence tomography (SD-OCT).

An objective assessment of the macular function can be performed by using electrophysiological methods such as focal or multifocal electroretinogram (Focal-ERG, mfERG). By Focal-ERG it is possible to evaluate the function of both preganglionic and ganglionic macular elements, whereas the first-order kernel study of

the mfERG provides information about the function of the preganglionic retinal elements (in particular cones and bipolar cells) [5, 6].

Both Focal-ERG and mfERG have been used in several studies to assess the macular function during postoperative (ILM peeling) follow-up [5, 7–10].

The aim of this study was to evaluate in patients with EMM whether the preoperative condition of integrity of the IS/OS junction may influence the postoperative visual acuity, the macular morphology (assessed by SD-OCT), and macular function (evaluated by mfERG) during 6 months of follow-up.

METHODS

Patients

In this observational study, 18 patients (mean age 72.5 ± 6.87 years) with idiopathic EMM, undergoing pars plana vitrectomy with ILM peeling, at the Ophthalmology Clinic of IRCCS Policlinico San Matteo, were enrolled. The clinical diagnosis of EMM was based on indirect binocular ophthalmoscopy with a +90 D non-contact lens (Volk Optical Inc., Ohio, USA) and on the SD-OCT examination (see below) which revealed an increase in macular volume associated with optically hyperreflective epiretinal echoes due to the presence of a membrane.

Since several pathologies may induce changes of the macula bioelectrical responses [5, 6], and their presence may represent potential confounding factors, patients enrolled in the present study were selected from a larger EMM cohort (52 patients) after exclusion of presence of dense lens opacities, ocular hypertension or glaucoma, diabetic retinopathy, drusen and age-related macular disease, other general diseases such as systemic hypertension, diabetes, connective tissue, or neurological diseases.

As per the report by Falkner-Radler et al. [4], our patients were divided into two groups according to the integrity of the IS/OS junction: the EMM-I group in which an intact IS/OS junction was identified by SD-OCT examination (see below) (11 patients, mean age 72.75 ± 3.49 years, providing 11 eyes; 5 phakic

patients) and the EMM-D group in which a disrupted IS/OS junction was observed by SD-OCT examination (7 patients, mean age 70.86 ± 10.79 years, providing 7 eyes; 5 phakic patients). Three eyes of the EMM-I group and three eyes of the EMM-D group were phakic (Chi-square $t = 0.0036$; $p = 0.9522$).

Evaluation of photoreceptor status was performed on the central part of the 1.5 mm of two perpendicular scans centered on the fovea. The intact IS/OS junction was identified as a continuous hyperreflective line; the disrupted IS/OS junction was identified as interruptions of the normal hyperreflective line. Classification was assessed by the agreement of two of the authors (GV, AF). In case of disagreement a third assessment was performed by one of the authors (LQ).

VA, mfERG, and SD-OCT were assessed in each enrolled patient at baseline (preoperative) and after 1, 3, and 6 month of follow-up after surgical treatment for EMM in each enrolled patient.

Surgical Treatment

All the patients underwent a 25-gauge pars plana vitrectomy with a solution of 0.15% trypan blue, 0.025% brilliant blue G, 4% polyethylene glycol (MembraneBlue-Dual) assisted epiretinal membrane (ERM)/ILM removal performed by a single surgeon (GV); no air–fluid exchange was performed during surgery. In phakic eyes, phacoemulsification with intraocular lens implantation was performed at the time of vitrectomy.

Visual Acuity Evaluation

Best-corrected VA was assessed by the modified ETDRS charts (Lighthouse, Low vision products, Long Island City, NY, USA) and expressed in logMAR values obtained at a distance of 4, 2, 1, and 0.5 m.

MfERG Recordings

The Espion D310 Profile Multifocal System (Diagnosys UK Ltd, Histon, Cambridge, UK) was used to record the mfERG.

In all eyes, mfERGs were binocularly recorded under photopic conditions in normal room illumination. Pupils were maximally pharmacologically dilated with 1% tropicamide to a diameter of 7–8 mm. Binocular mfERG recording was preferred for helping subjects to have a stable target fixation. At every mfERG examination, each patient positively reported that he/she could clearly perceive the cross fixation target. The eye's position was continuously monitored by a fixation camera to track patient gaze.

The cornea was anesthetized with 0.4% oxybuprocaine. MfERGs were recorded bipolarly between an active electrode [Dawson-Trick-Litzkow (DTL) thread electrodes] and a reference Ag/AgCl electrode placed on the temple. A small Ag/AgCl skin ground electrode was placed at the center of the forehead. Inter-electrode resistance was less than 5 K Ω .

The multifocal achromatic stimulus, consisting of 61 scaled hexagons, was displayed on a high-resolution liquid crystal display (LCD), black-and-white 32" (diagonal) monitor (size 70 cm width and 39.5 cm height) with a frame rate of 75 Hz (base period for stimulus presentation was 13.3 ms). The hexagon-shaped stimuli are arranged along several concentric rings and are randomly alternated between black (1 cd/m²) and white (400 cd/m²), with the on-off string of each hexagon determined according to a 14-bit m-sequence. This resulted in a contrast of 99%. The luminance of the monitor screen was 200 cd/m² and a central fixation red cross was used as target in the center of the stimulation field. The eccentricity of the outermost ring of the 61-hexagon array is about 30° (radius from the fixation point to edge of display).

The m-sequence had 2^{13-1} elements and total recording time was approximately 5 min. Total recording time was divided into nine segments, with a duration of 30 s each. Between segments, the subject was allowed to rest for a few seconds.

The signal was amplified (gain 100,000) and filtered (band pass 10–100 Hz) by LPC2000 Flash Utility software V2.2.1. After automatic rejection of artifacts (and blinks) and application of line current (50 or 60 Hz) interference filter (or

Runtime Mains Rejection), and automatic rejection of the bioelectrical responses with noise greater than 1 μ V root mean square (RMS), the system software (V6.58.2) provided the first-order kernel response, which was normalized considering the ratio between the bioelectrical responses and the relative retinal area from which the signals were collected. In the first-order kernel response, different peaks (labeled with the letter indicating the negative, N, and positive, P, polarity and the sequential number of appearance) were identified in a time after the 0 ms corresponding to the presentation of the visual stimuli.

In the analysis of normalized mfERG responses, we considered the peak-to-peak amplitude between N1 and P1 peaks, called response amplitude density (RAD) measured in nanovolts per degree² (nV/deg²).

MfERG ring analysis was selected to differentiate changes of the bioelectrical responses of the foveal region with respect to the more eccentric macular areas. We analyzed the averaged response obtained from two concentric annular retinal regions (rings, R) centered on the fovea. Therefore, we analyzed the N1–P1 RADs derived from 0° to 5° (R1) and from 5° to 10° (R2).

SD-OCT Assessment

All patients underwent structural SD-OCT scan using the Heidelberg Spectralis imaging platform (version 1.10.4.0, Heidelberg Engineering, Heidelberg Germany) after pupil dilation. The SD-OCT imaging protocol consisted of at least 20° × 15° volume scans of the macula area with 19 B-scans.

A qualitative analysis was performed to evaluate the integrity of the inner segment and outer segment photoreceptor junction. Quantitative analysis of central retinal thickness (CRT), including the overall, the inner (I-CRT), and outer (O-CRT) CRT, and macular volume (MV) were automatically obtained from the macular map centered to the fovea, through inbuilt software of the Heidelberg Spectralis (version 1.10.2.0).

Table 1 Mean values of logMAR visual acuity, mfERG responses recorded from two annular areas (rings = R) with increasing eccentricity from the fovea to the retinal mid-periphery: 0–5° (R1) and 5–10° (R2), SD-OCT central retinal thickness (overall, inner, and outer), and macular volume assessed in patients with idiopathic

epimacular membrane (EMM) with preoperative integrity of inner segment/outer segment junction (EMM-I) or without preoperative integrity of inner segment/outer segment junction (EMM-D) at baseline and 1, 3, and 6 months after EMM peeling

	Group EMM-I (N = 11)		Statistical significance ^a	Group EMM-D (N = 7)		Statistical significance ^a
	Mean	SD		Mean	SD	
Visual acuity (logMAR)						
Baseline	0.747	0.237		0.689	0.191	
1 month	0.560	0.206	*	0.760	0.252	NS
3 months	0.415	0.151	*	0.617	0.143	NS
6 months	0.363	0.212	*	0.677	0.158	NS
mfERG R1: N1–P1 RAD (log nV/deg ²)						
Baseline	24.409	7.334		31.229	6.137	
1 month	25.655	6.979	NS	34.171	10.462	NS
3 months	20.945	7.925	NS	28.086	7.425	NS
6 months	25.009	7.766	NS	27.543	4.153	NS
mfERG R2: N1–P1 RAD (log nV/deg ²)						
Baseline	15.136	2.572		17.243	1.780	
1 month	15.100	4.593	NS	19.843	6.859	NS
3 months	12.873	4.585	NS	18.771	2.205	NS
6 months	14.964	3.856	NS	17.114	4.586	NS
SD-OCT: central overall retinal thickness (μm)						
Baseline	480.500	96.848		469.143	82.414	
1 month	426.167	49.593	NS	437.714	27.891	NS
3 months	414.833	36.910	*	429.857	44.518	NS
6 months	399.417	31.480	*	415.571	38.113	NS
SD-OCT: central inner retinal thickness (μm)						
Baseline	395.250	98.050		383.571	81.289	
1 month	340.417	49.397	NS	352.286	32.418	NS
3 months	328.417	38.550	*	341.571	45.003	NS
6 months	314.667	33.530	*	327.429	38.656	NS
SD-OCT: central outer retinal thickness (μm)						
Baseline	85.250	4.309		85.571	4.429	
1 month	85.750	4.938	NS	85.429	6.779	NS
3 months	86.417	6.417	NS	88.286	6.775	NS

Table 1 continued

	Group EMM-I (<i>N</i> = 11)		Statistical significance ^a	Group EMM-D (<i>N</i> = 7)		Statistical significance ^a
	Mean	SD		Mean	SD	
6 months	84.750	4.137	NS	88.143	6.719	NS
SD-OCT: macular volume (mm ³)						
Baseline	9.734	1.136		11.387	0.902	
1 months	9.341	0.844	NS	9.953	0.494	*
3 months	9.109	0.820	NS	9.380	0.980	*
6 months	8.677	0.801	*	9.169	0.590	*

SD standard deviation, RAD response amplitude density

* $p < 0.05$, NS $p > 0.05$

^a One-way ANOVA at each time of follow-up (1, 3, and 6 months) with respect to baseline

The research followed the tenets of the Declaration of Helsinki and the study was approved by the local institutional review board (IRB) (Scientific Committee of the Section of Ophthalmology, University of Pavia, IRCCS Fondazione Policlinico San Matteo, Pavia, Italy). Each patient signed an informed consent.

Statistical Analysis

The Anderson–Darling and Kolmogorov–Smirnov tests were applied to verify that data were normally distributed. Only one eye was chosen for each patient.

During the follow-up, the differences in VA, mfERG, and SD-OCT values observed in individual eyes with respect to baseline values (values detected at 1, 3, and 6 months of follow-up minus those detected at baseline) were calculated by performing a logarithmic transformation to better approximate a normal distribution. The statistical significance of the mean of individual differences of these parameters detected in EMM-I and EMM-D groups were evaluated by analysis of variance (ANOVA) using Bonferroni's correction for multiple comparisons. The changes in absolute values of VA, mfERG, and SD-OCT values with respect to baseline were evaluated by ANOVA corrected for multiple comparisons using Bonferroni's correction separately for each group.

Pearson's correlation was used to assess the relationship between the differences (logarithmic values at 1, 3, and 6 months minus logarithmic values at baseline) in VA and mfERG and SD-OCT data. All statistical analyses were performed using SPSS V.26 (Statistical Package for Social Science IBM), and a p value less than 0.05 was considered as statistically significant.

RESULTS

Table 1 reports the mean of absolute values of VA, mfERG RAD, and SD-OCT parameters detected in EMM-I and EMM-D groups at baseline and during the follow-up (1, 3, and 6 months) and relative statistical analyses.

Table 2 presents the mean of individual differences (1, 3, and 6 months of follow-up minus baseline values) in VA, mfERG RAD, and SD-OCT parameters detected in EMM-I and EMM-D groups and relative statistical analyses.

Visual Acuity Data

At 1, 3, and 6 months of follow-up, in comparison to baseline, EMM-I eyes showed a significant ($p < 0.05$) increase in VA, whereas no significant ($p > 0.05$) differences in EMM-D eyes were found.

The mean of individual differences in VA observed in EMM-I eyes after 1 and 3 months of

Table 2 Mean values of the individual differences (1, 3, and 6 months after surgical treatment minus baseline) in visual acuity, in mfERG responses recorded from two annular areas (rings = R) with increasing eccentricity from the fovea to the retinal mid-periphery: 0–5° (R1) and 5–10° (R2), in SD-OCT central retinal

thickness (overall, inner, and outer), and macular volume observed in patients with idiopathic epimacular membrane (EMM) with preoperative integrity of inner segment/outer segment junction (EMM-I) or without preoperative integrity of inner segment/outer segment junction (EMM-D) subjected to EMM peeling

	Group EMM-I (<i>N</i> = 11)		Group EMM-D (<i>N</i> = 7)		Statistical significance ^a
	Mean	SD	Mean	SD	
Difference in visual acuity (logMAR)					
1 month minus baseline	– 0.187	0.313	0.071	0.192	NS
3 months minus baseline	– 0.331	0.326	– 0.071	0.123	NS
6 months minus baseline	– 0.383	0.344	– 0.011	0.090	*
mfERG R1: difference in N1–P1 RAD (log nV/deg ²)					
1 month minus baseline	0.025	0.145	0.029	0.160	NS
3 months minus baseline	– 0.072	0.148	– 0.052	0.124	NS
6 months minus baseline	0.009	0.166	– 0.051	0.0754	NS
mfERG R2: difference in N1–P1 RAD (log nV/deg ²)					
1 month minus baseline	– 0.012	0.144	0.043	0.144	NS
3 months minus baseline	– 0.087	0.188	0.036	0.048	NS
6 months minus baseline	– 0.010	0.144	– 0.014	0.092	NS
SD-OCT: difference in central overall retinal thickness (log μm)					
1 month minus baseline	– 0.047	0.053	– 0.024	0.057	NS
3 months minus baseline	– 0.057	0.067	– 0.034	0.066	NS
6 months minus baseline	– 0.073	0.065	– 0.048	0.064	NS
SD-OCT: difference in central inner retinal thickness (log μm)					
1 month minus baseline	– 0.057	0.064	– 0.023	0.068	NS
3 months minus baseline	– 0.071	0.082	– 0.045	0.079	NS
6 months minus baseline	– 0.089	0.077	– 0.063	0.075	NS
SD-OCT: difference in central outer retinal thickness (log μm)					
1 month minus baseline	0.002	0.034	– 0.001	0.028	NS
3 months minus baseline	0.005	0.039	0.013	0.035	NS
6 months minus baseline	– 0.002	0.025	0.012	0.038	NS
SD-OCT: difference macular volume (log mm ³)					
1 month minus baseline	– 0.017	0.035	– 0.058	0.024	*
3 months minus baseline	– 0.028	0.037	– 0.085	0.039	*

Table 2 continued

	Group EMM-I (N = 11)		Group EMM-D (N = 7)		Statistical significance ^a
	Mean	SD	Mean	SD	
6 months minus baseline	- 0.049	0.042	- 0.094	0.023	*

SD standard deviation, RAD response amplitude density

* $p < 0.05$, NS $p > 0.05$

^a One-way ANOVA between EMM-I and EMM-D groups

follow-up with respect to baseline were greater than those observed in EMM-D eyes without reaching a level of statistical significance ($p = 0.06$); at 6 months of follow-up a significant ($p < 0.05$) difference between EMM-I and EMM-D eyes was found.

MfERG Data

With respect to baseline, at 1, 3, and 6 months of follow up in both EMM-I and EMM-D groups no significant ($p > 0.05$) changes in R1 and R2 RADs were observed. The mean of individual differences in R1 and R2 RADs observed during the follow-up were not significantly ($p > 0.05$) different between EMM-I and EMM-D eyes.

SD-OCT Data

In the EMM-I group, at 1 month of follow-up, the mean values of CRT, I-CRT, O-CRT, and MV were not significant different ($p > 0.05$) when compared to baseline ones. At 3 and 6 months of follow-up, the mean values of CRT and I-CRT were significantly ($p < 0.05$) reduced, while those of O-CRT were unmodified ($p > 0.05$). A significant ($p < 0.05$) reduction of MV values was only detected at 6 months (Fig. 1).

In the EMM-D group, at 1, 3, and 6 months of follow-up, the values of CRT, I-CRT, and O-CRT were not significantly different ($p > 0.05$) with respect to those observed at baseline. The MV values were significantly reduced at 1, 3, and 6 months of follow-up (Fig. 2).

The mean of individual differences in CRT, I-CRT, and O-CRT values observed at 1, 3, and 6 months of follow-up in the EMM-I group were

not significantly different ($p > 0.05$) with respect to those observed in the EMM-D group, while MV values were significantly different ($p > 0.05$) between EMM-I and EMM-D groups.

Correlations Between Visual Acuity, mfERG, and SD-OCT Data

In EMM-I eyes, the differences (1, 3, and 6 months of follow-up minus baseline) in VA were not significantly correlated ($p > 0.05$) to the corresponding differences of mfERG (R1 and R2 RADs) and SD-OCT (CRT, I-CRT, O-CRT, and MV) parameters.

In EMM-I eyes, the differences (1, 3, and 6 months of follow-up minus baseline) in VA were not significantly correlated ($p > 0.05$) to the corresponding differences of mfERG (R1 and R2 RADs) parameters. Only at 6 months of follow-up was a significant correlation ($p < 0.05$) between VA and I-CRT and MV values found.

Table 3 reports the linear correlation between the differences in VA and those in I-CRT and MV detected in EMM-I and EMM groups.

DISCUSSION

The aim of our study was to evaluate whether the preoperative integrity of the IS/OS junction may influence the postoperative visual acuity and macular morpho-functional outcomes in patients with EMM. Therefore, we compared the results of VA, SD-OCT, and mfERG during 6 months of follow-up after the surgical treatment (pars plana vitrectomy with EMM removal and ILM peeling) of the EMM in patients with

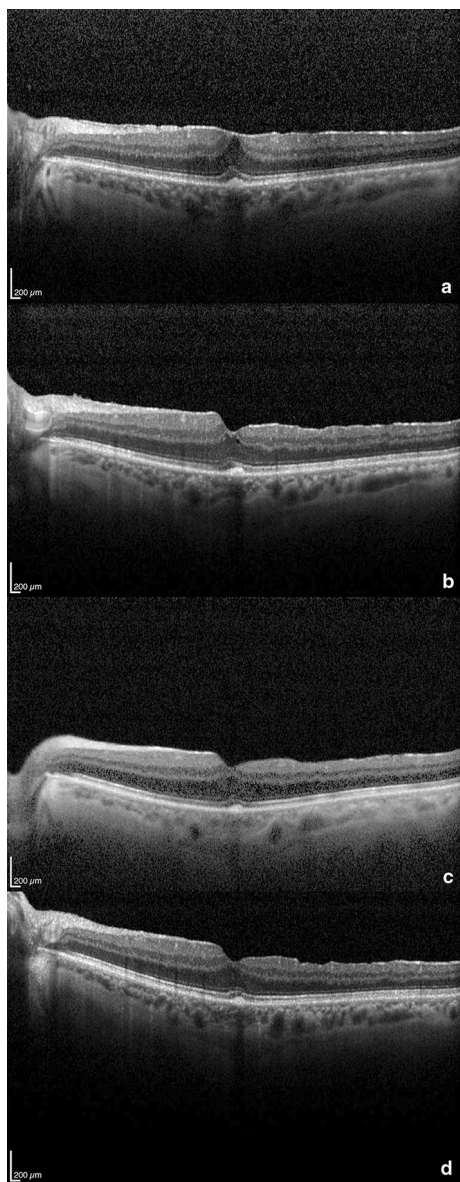


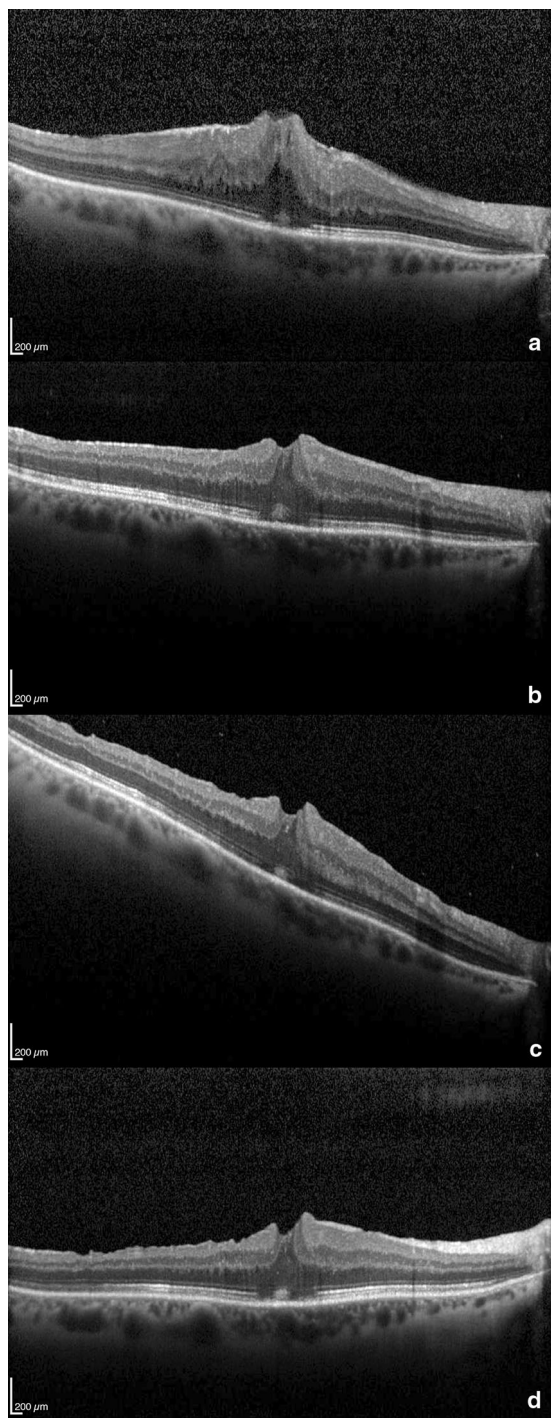
Fig. 1 Spectral domain optical coherence tomography of intact inner segment/outer segment junction of photoreceptors: preoperative (a), after 1 month (b), 3 months (c), 6 months (c) postoperatively. The scans show a successful removal of the epiretinal membrane and a progressive restoration of foveal depression with reduction of retinal thickness. IS/OS junction has a normal appearance before and after surgery. Visual acuity improved from 1.12 to 0.44 logMAR

preoperative EMM with or without integrity of the IS/OS junction (EMM-I and EMM-D groups, respectively).

During the follow-up, in EMM-I eyes a significant increase in VA was detected and this is in agreement with results reported by Falkner-Radler et al. [4] and is supported by data showing that integrity of the IS/OS junction indicates a normal alignment of photoreceptors with the other retinal elements leading to normal visual function [11].

In EMM eyes with integrity of the IS/OS junction, the increase in VA was independent from the macular function evaluated by mfERG, as suggested by the lack of significant linear correlation between VA and mfERG RADs. Since it is well known that the mfERG responses reflect the bioelectrical activity of the pre-ganglionic elements (photoreceptors and bipolar cells) [12], it is likely that their function does not contribute to the postoperative increase in VA. In fact, the bioelectrical response of the pre-ganglionic elements was unmodified after surgical treatment. This finding is in contrast with other studies reporting either worsening [6, 9] or improvement [10] of mfERG responses after macular surgery for EMM peeling. In addition, this functional finding was associated, but not significantly correlated, to unchanged thickness of the outer retinal layers of the macula region (i.e., not significant changes of O-CRT). Thus, when there is integrity of the IS/OS junction, it is likely that the increase in VA can be ascribed to a better morpho-functional condition of the inner retina (ganglion cells and their fibers) following the surgical treatment.

In relation to the morphological condition, a reduction of the thickness of the inner retinal layers of the macula region (i.e., significant changes of I-CRT) was detected in EMM-I eyes and this may be due to a reduced tractive effect of the EMM on the intraretinal elements [5]. However, in EMM-I eyes, the significant reduction of I-CRT was associated, but not significantly correlated, with the increase in VA. Therefore, it is likely that the function of the inner retinal layers may play an important role in the improvement of the VA. Unfortunately, the analysis of the first-order kernel of the mfERG does not allow one to evaluate the function of the inner retina and in this study we are not able to provide information about the possible increase of the inner retina function.



◀ **Fig. 2** Spectral domain optical coherence tomography of disrupted inner segment/outer segment junction of photoreceptors: preoperative (a), after 1 month (b), 3 months (c), 6 months (d) postoperatively. IS/OS junction has focal interruptions in the foveal region before and after surgery. Despite the successful removal of epiretinal membrane and the reduction of retinal thickness, visual acuity showed a very slight improvement from 0.72 to 0.62 logMAR

Focal ERG in response to contrast visual stimuli [5]), an increase of the function of these retinal elements was detected and this was significantly correlated with the improvement of the VA [5].

During the follow-up, EMM-D eyes did not significantly change in VA and this is in accordance with the previously mentioned evidence reported by Falkner-Radler et al. [4]. In this group, with respect to baseline, the macular morphological thickness was not significantly modified during the follow-up, whereas a significant reduction of the macular volume was found.

VA results should be ascribed to the effects of EMM on the macular morphology and function. In fact, in the presence of “severe” EMM [13], and when the integrity of the IS/OS junction is not present, Arichika et al. [14] observed an increased macular thickness for greater involvement of intraretinal elements. These structural macular changes may induce abnormalities of photoreceptors [12] that in the majority of cases may be irreversible after surgery, with consequent absence of recovery in VA [15].

In our EMM-D eyes, while the MV was reduced, not significant changes of both inner and outer CRT were found. This led us to hypothesize that the peeling of the EMM is not sufficient to restore the intraretinal structure with possible persistence of distortion of the macular elements and consequent lack of VA recovery. Nevertheless it is worth noting that the differences in VA were significantly related to the corresponding reduction in I-CRT and MV.

In EMM-D eyes no changes in the bioelectrical activity of the preganglionic elements (unmodified mfERG RADs) after EMM peeling were detected. Since Focal ERG was not

Nevertheless, it is interesting to report that when more appropriate electrophysiological methods were used to evaluate the effects of IML peeling on the ganglion cell function (i.e.,

Table 3 Linear correlation (Pearson's test) between the individual differences (1, 3, and 6 months after surgical treatment minus baseline) in visual acuity and the corresponding differences in mfERG responses recorded from two annular areas (rings = R) with increasing eccentricity from the fovea to the retinal mid-periphery: 0–5° (R1) and 5–10° (R2), in SD-OCT central inner retinal thickness, and in

macular volume assessed in patients with idiopathic epimacular membrane (EMM) with preoperative integrity of inner segment/outer segment junction (EMM-I) or without preoperative integrity of inner segment/outer segment junction (EMM-D) subjected to EMM peeling

	Difference in visual acuity (logMAR)			
	Group EMM-I		Group EMM-D	
	<i>r</i>	<i>P</i>	<i>r</i>	<i>P</i>
R1 RAD difference 1 month/baseline (log nV/deg ²)	– 0.319	0.337	– 0.698	0.080
R1 RAD difference 3 months/baseline (log nV/deg ²)	0.152	0.655	– 0.100	0.830
R1 RAD difference 6 months/baseline (log nV/deg ²)	0.318	0.339	– 0.461	0.297
Central inner retinal thickness difference 1 month/baseline (log μm)	– 0.044	0.896	– 0.588	0.165
Central inner retinal thickness difference 3 months/baseline (log μm)	0.075	0.825	0.699	0.080
Central inner retinal thickness difference 6 months/baseline (log μm)	– 0.304	0.362	0.849	0.016*
Macular volume difference 1 month/baseline (log mm ³)	0.155	0.629	0.006	0.989
Macular volume difference 3 months/baseline (log mm ³)	0.184	0.566	0.492	0.261
Macular volume difference 6 months/baseline (log mm ³)	– 0.092	0.775	0.775	0.040*

RAD response amplitude density

*Significant correlation ($p < 0.05$)

performed in this study, we were not able to establish whether the reduction of the macular volume should induce an increased function of the inner retina, and since no correlations were found between mfERG and MV differences, it is likely that the function of the preganglionic elements is not influenced by macular structural changes when there is a lack of integrity of the IS/OS junction.

CONCLUSION

Results obtained in this pilot study suggest that the preoperative evaluation of the integrity of the IS/OS junction is relevant in postoperative outcomes. The recovery in VA was higher in EMM-I eyes than in EMM-D eyes. Postoperative recovery was not associated with morphology of the outer retina (photoreceptor and outer nuclear layer) and the function of preganglionic elements.

Small sample size is a limitation of the present study; our preliminary results need to be confirmed in a larger cohort of patients.

ACKNOWLEDGEMENTS

We thank the participants of the study.

Funding. No funding or sponsorship was received for this study or publication of this article. The contribution of the Bietti Foundation for this study was supported the Italian Ministry of Health and Fondazione Roma.

Authorship. All named authors meet the International Committee of Medical Journal Editors (ICMJE) criteria for authorship for this article, take responsibility for the integrity of the work as a whole, and have given their approval for this version to be published.

Disclosures. All authors (Giulio Ruberto, Vincenzo Parisi, Giulio Vandelli, Alessandro Falcione, Federica Manzoni, Ivano Riva, and Luciano Quaranta) declare that they have nothing to disclose.

Compliance with Ethics Guidelines. The research followed the tenets of the Declaration of Helsinki and the study was approved by the local institutional review board (IRB) (Scientific Committee of the Section of Ophthalmology, University of Pavia, IRCCS Fondazione Policlinico San Matteo, Pavia, Italy). Each patient signed an informed consent.

Data Availability. All authors had full access to all of the data in this study and take complete responsibility for the integrity of the data and accuracy of the data analysis. The datasets generated and/or analyzed during the current study are available from the corresponding author on reasonable request.

REFERENCES

1. Bu SC, Kuijer R, Li XR, et al. Idiopathic epiretinal membrane. *Retina*. 2014;34:2317–35.
2. Schechet SA, DeVience E, Thompson JT. The effect of internal limiting membrane peeling on idiopathic epiretinal membrane surgery, with a review of the literature. *Retina*. 2017;37:873–80.
3. Park DW, Dugel PU, Garda J, et al. Macular pucker removal with and without internal limiting membrane peeling: pilot study. *Ophthalmology*. 2003;110:62–4.
4. Falkner-Radler CI, Glittenberg C, Hagen S, Benesch T, Binder S. Spectral-domain optical coherence tomography for monitoring epiretinal membrane surgery. *Ophthalmology*. 2010;117:798–805.
5. Parisi V, Coppè AM, Gallinaro G, Stirpe M. Assessment of macular function by focal electroretinogram and pattern electroretinogram before and after epimacular membrane surgery. *Retina*. 2007;27:312–20.
6. Hood DC. Assessing retinal function with the multifocal technique. *Prog Retin Eye Res*. 2000;19:607–47.
7. Moschos M, Apostolopoulos M, Ladas J, et al. Assessment of macular function by multifocal electroretinogram before and after epimacular membrane surgery. *Retina*. 2001;21:590–5.
8. Tari SR, Vidne-Hay O, Greenstein VC, Barile GR, Hood DC, Chang S. Functional and structural measurements for the assessment of internal limiting membrane peeling in idiopathic macular pucker. *Retina*. 2007;27:567–72.
9. Lai TY, Kwok AK, Au AW, Lam DS. Assessment of macular function by multifocal electroretinography following epiretinal membrane surgery with indocyanine green-assisted internal limiting membrane peeling. *Graefes Arch Clin Exp Ophthalmol*. 2007;245:148–54.
10. Koutsandrea CN, Apostolopoulos MN, Alonistiotis DA, et al. Indocyanine green-assisted epiretinal membrane peeling evaluated by optical coherence tomography and multifocal electroretinography. *Clin Ophthalmol*. 2007;1:535–44.
11. Wong IY, Iu LP, Koizumi H, Lai WW. The inner segment/outer segment junction: what have we learnt so far? *Curr Opin Ophthalmol*. 2012;23:210–8.
12. Hood DC, Frishman LJ, Saszik S, Viswanathan S. Retinal origins of the primate multifocal ERG: implications for the human response. *Invest Ophthalmol Vis Sci*. 2002;43:1673–813.
13. Gass JDM. *Stereoscopic atlas of macular disease*. St Louis: Mosby-Year Book; 1987. p. 716–7.
14. Arichika S, Hangai M, Yoshimura N. Correlation between thickening of the inner and outer retina and visual acuity in patients with epiretinal membrane. *Retina*. 2010;30:503–8.
15. Suh MH, Seo JM, Park KH, Yu HG. Associations between macular findings by optical coherence tomography and visual outcomes after epiretinal membrane removal. *Am J Ophthalmol*. 2009;147:473–80.