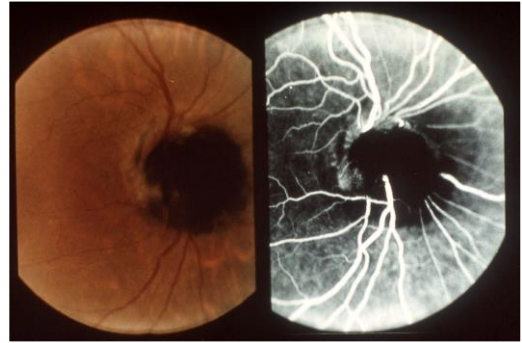


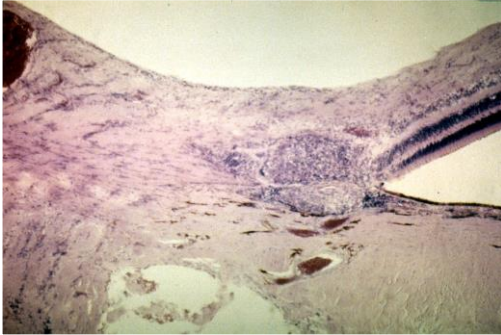
Tumori del nervo ottico

1



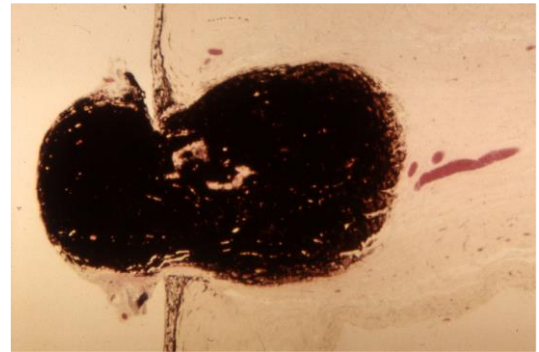
Melanocytoma

2



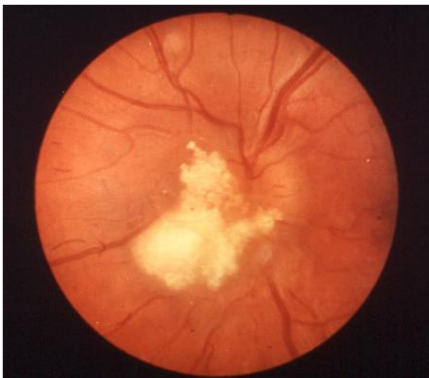Histopathology of a sarcoid granuloma in the optic nerve head

3



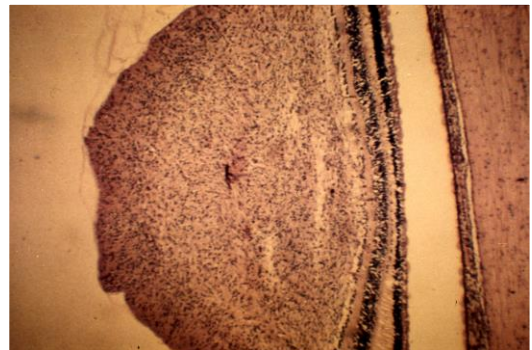
Melanocytoma: histopathology

4



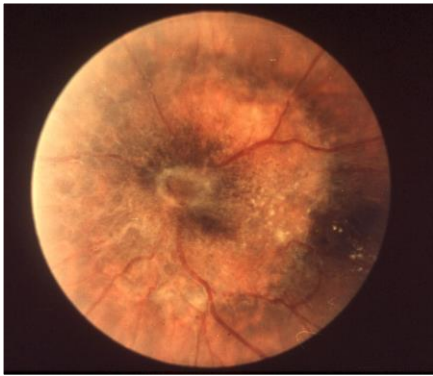Astrocytic hamartoma

5



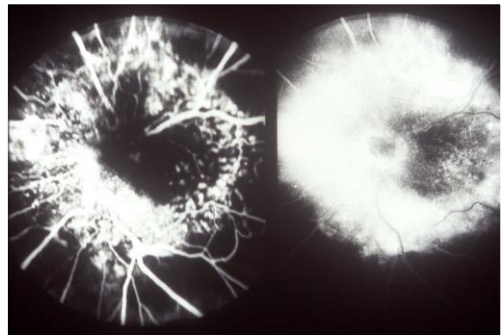
Astrocytic hamartoma: histopathology

6



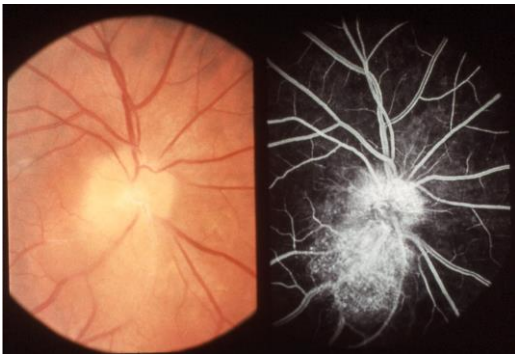
Pigmented epithelial hamartoma

7



Pigmented epithelial hamartoma: fluorescein angiogram

8



Capillary angioma of the optic disc

9